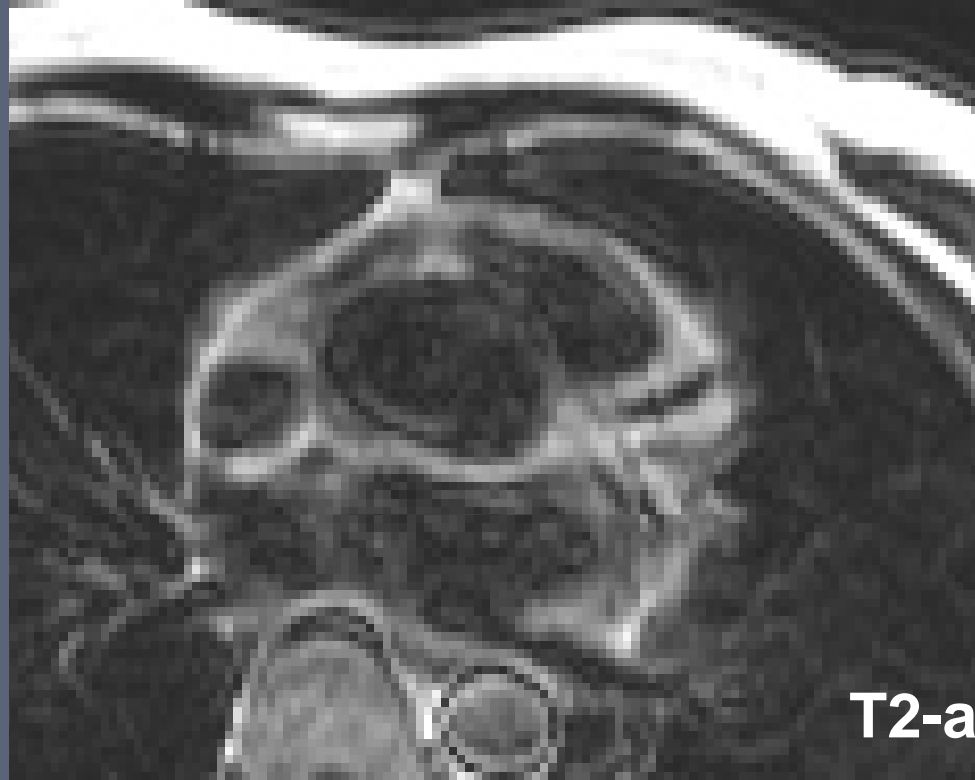


Case 2: 53yr / F

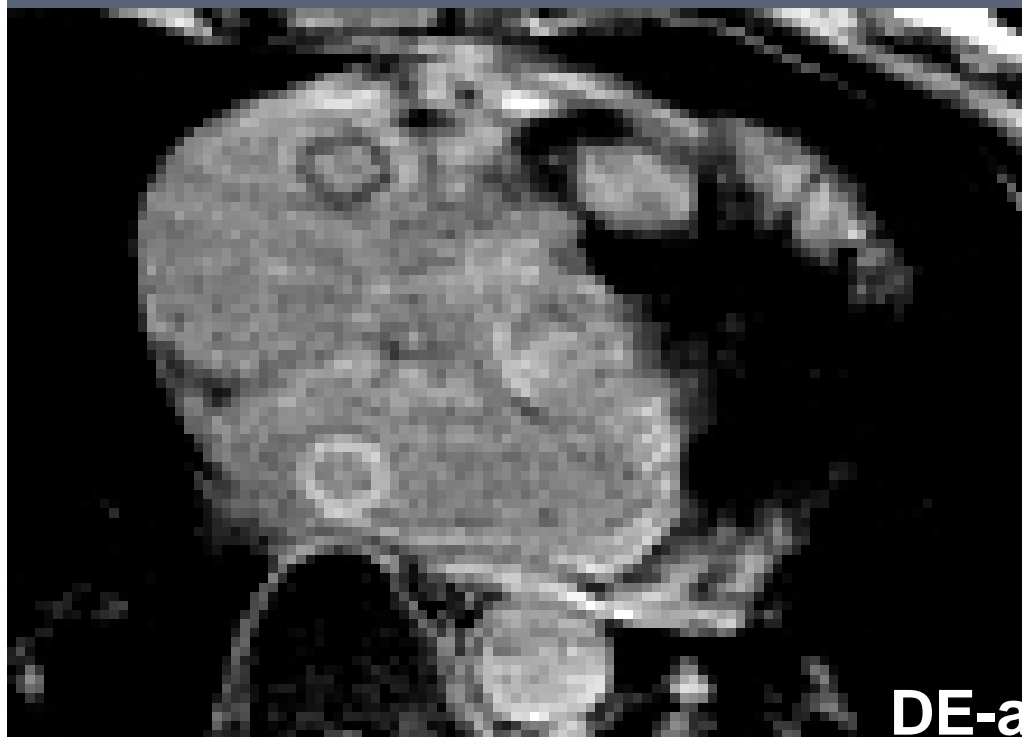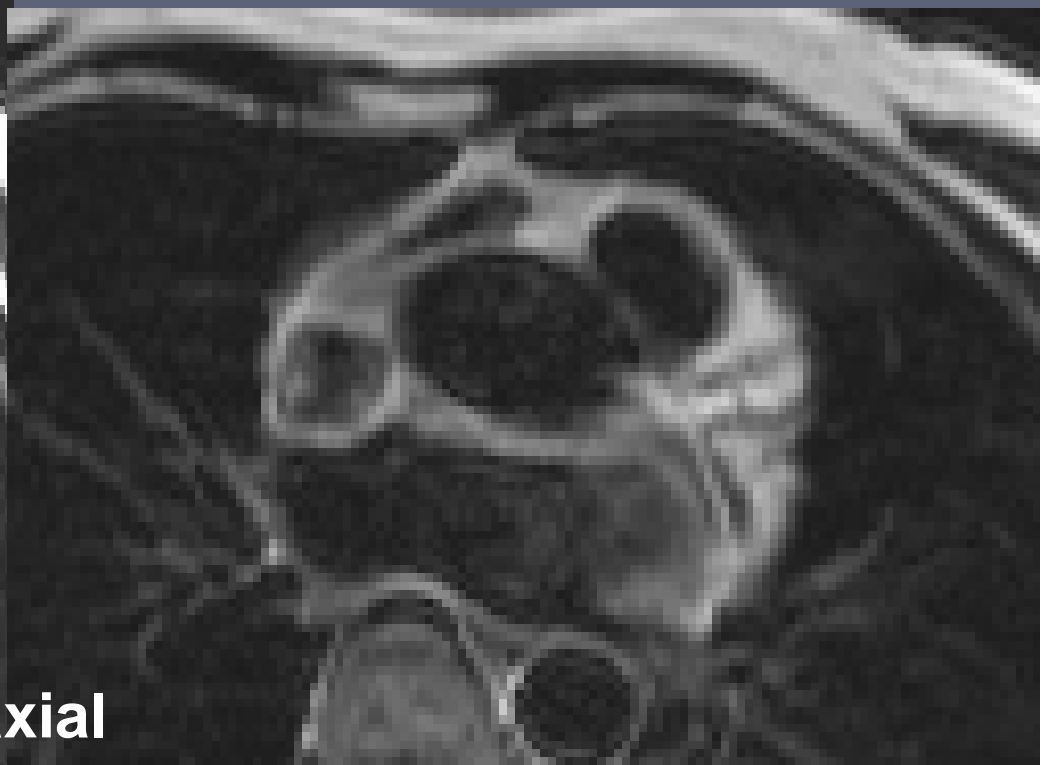
- C.C. : palpitation (5 days)
- Headache , chill, myalgia (2 week ago)

Presented by Joon Won Kang, Tae-Hwan Lim.

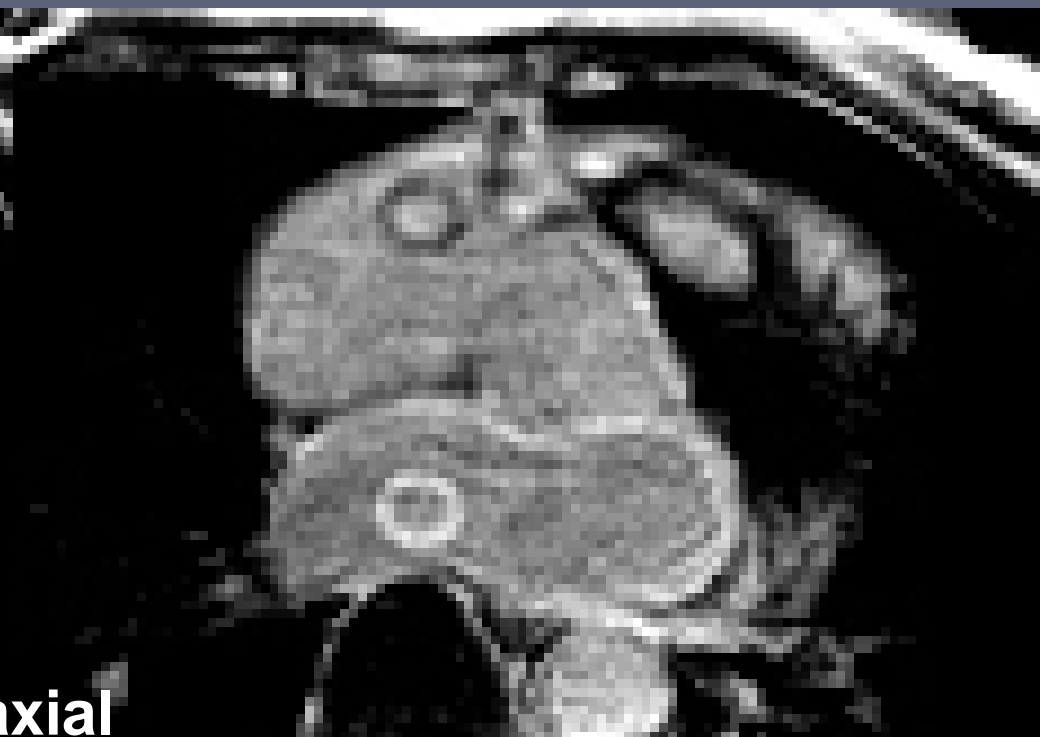Ulsan University Asan Medical Center (AMC), Seoul, Korea

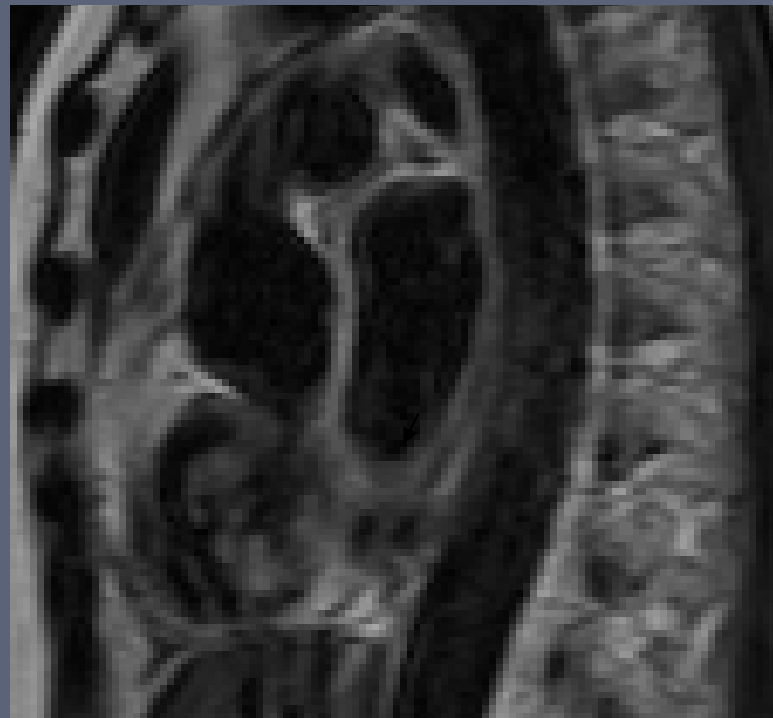
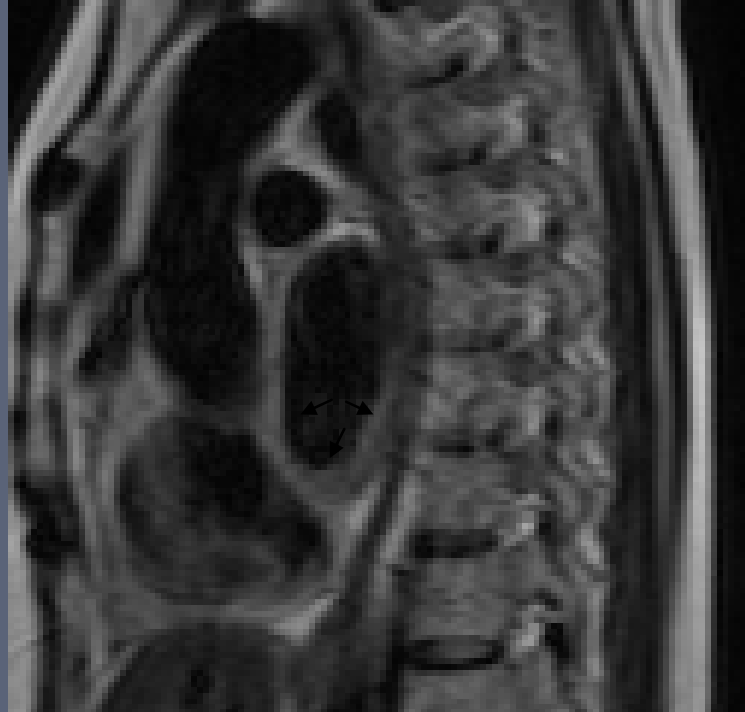
T2-axial

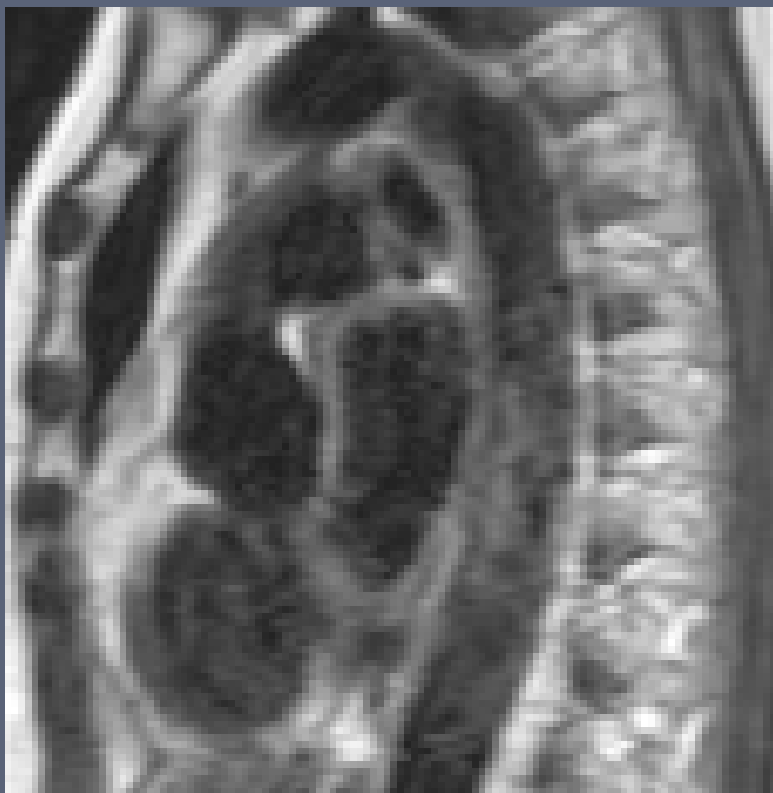
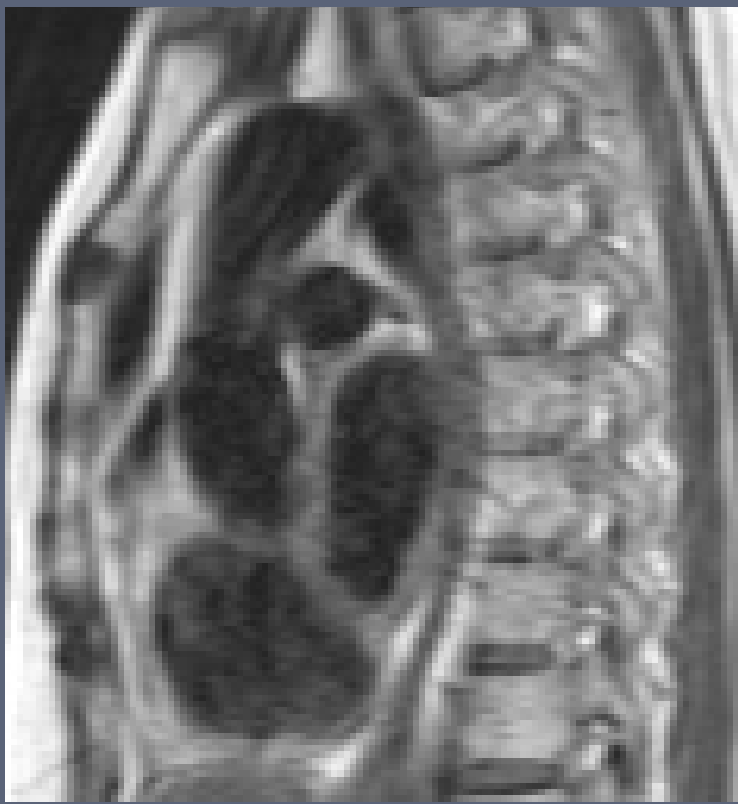
DE-axial

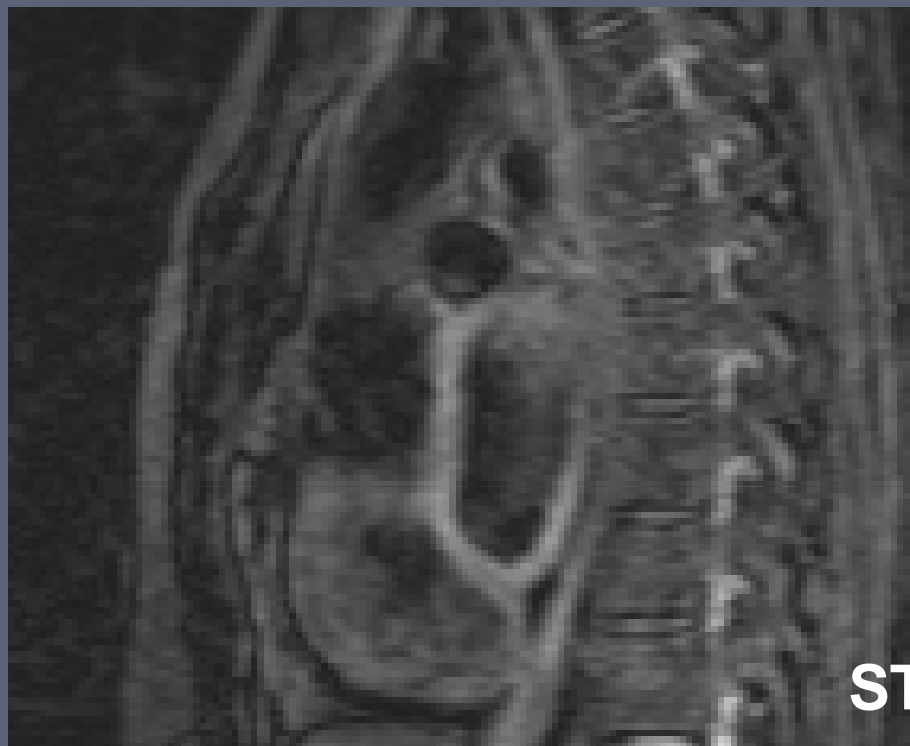



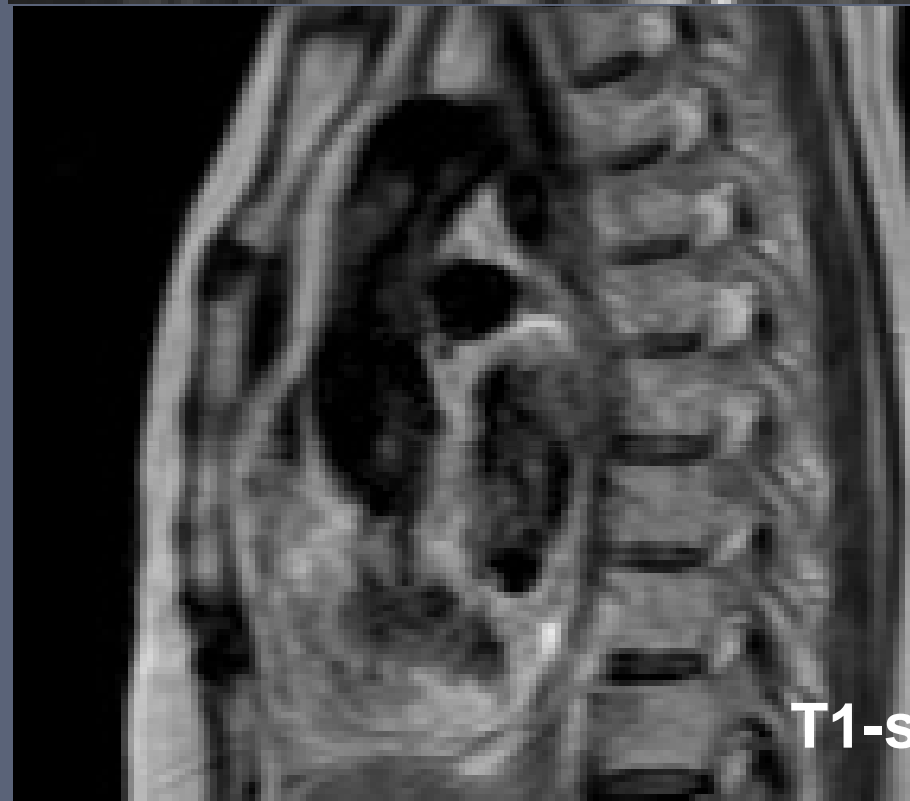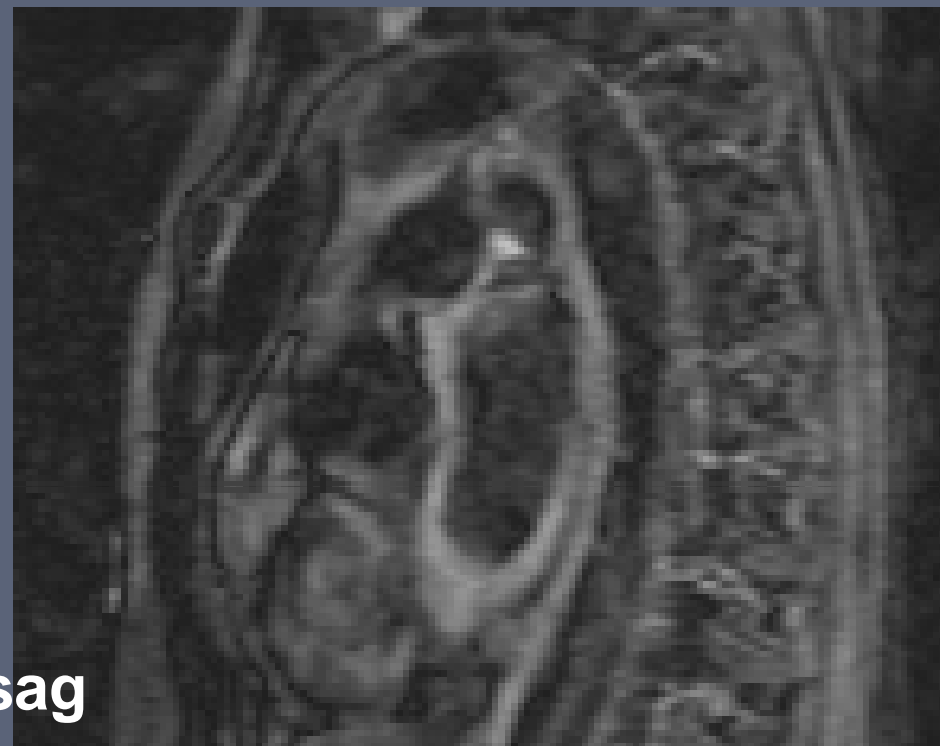T2-sag



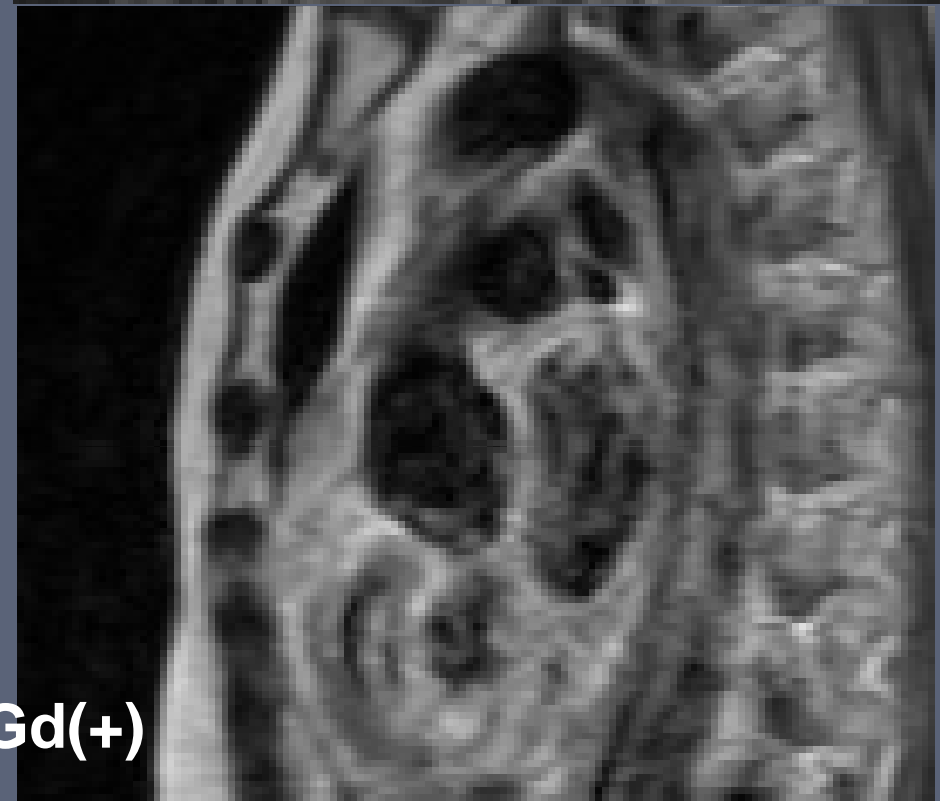
T1-sag

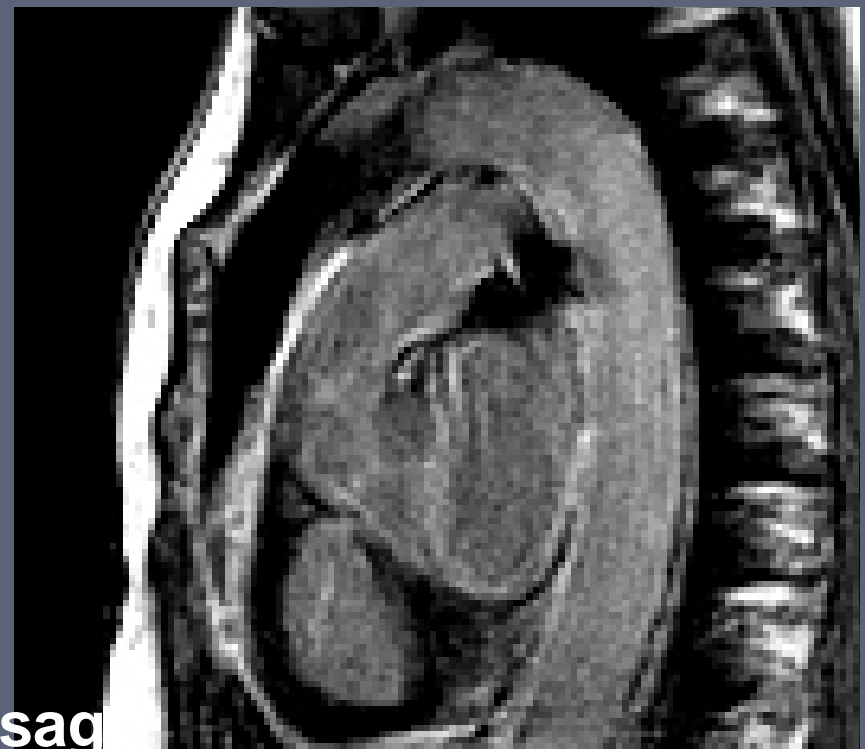
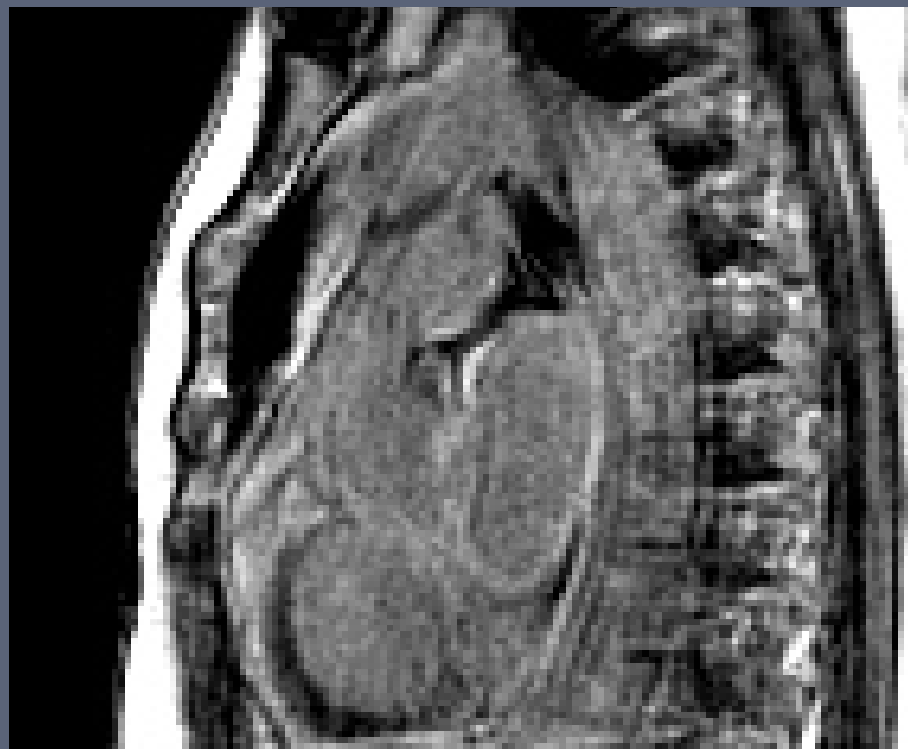
STIR-sag

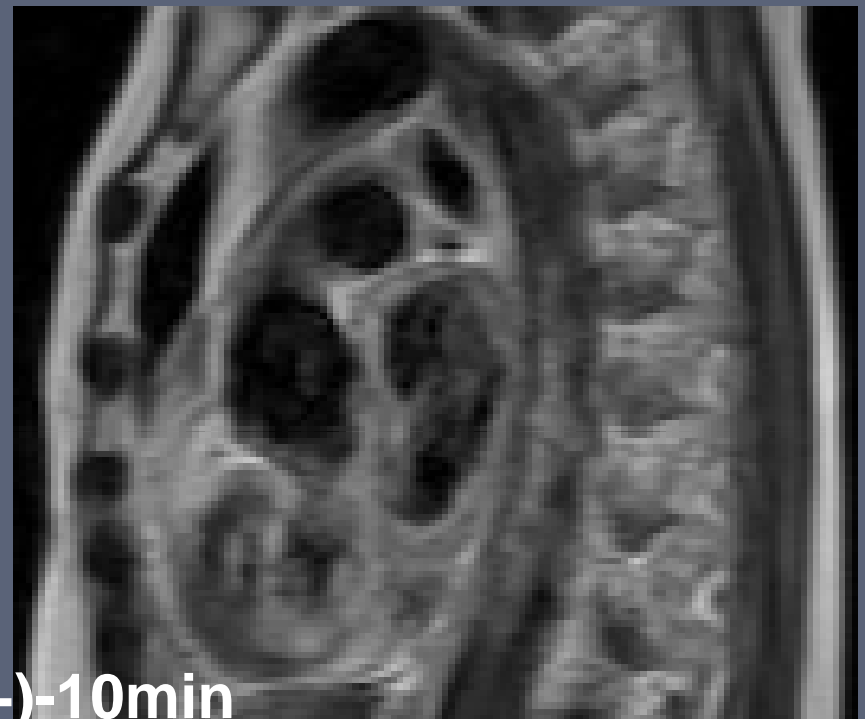
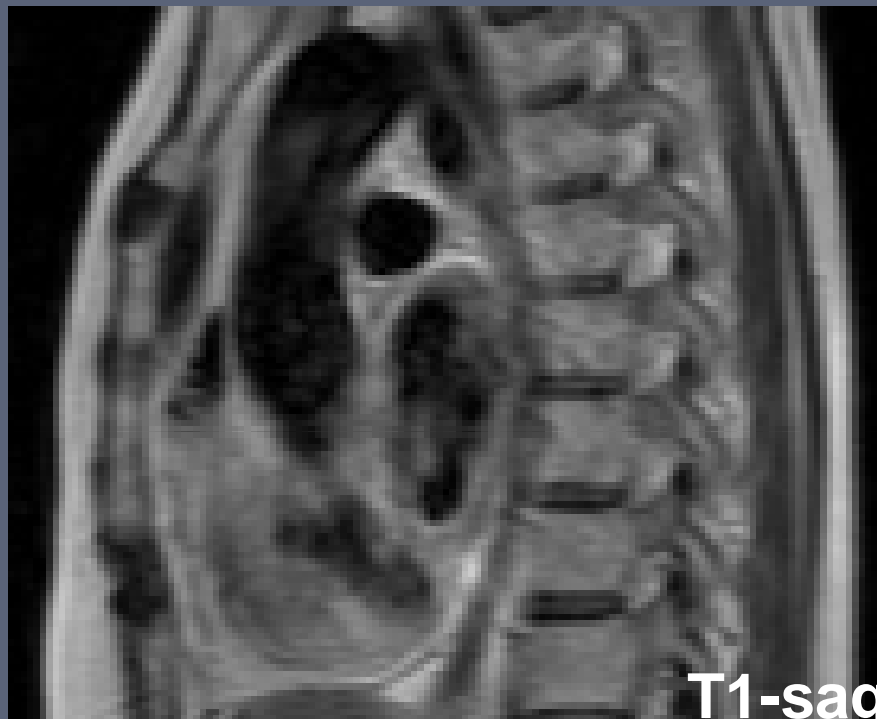
T1-sag-Gd(+)

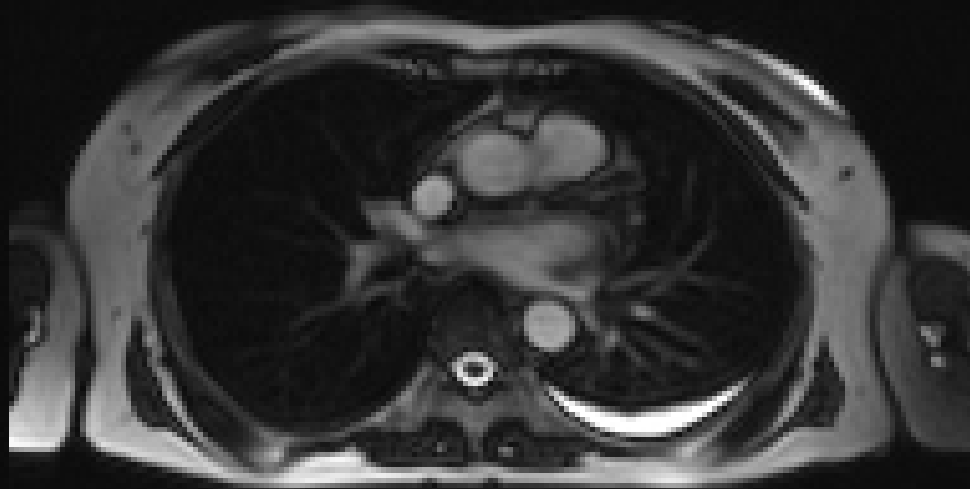




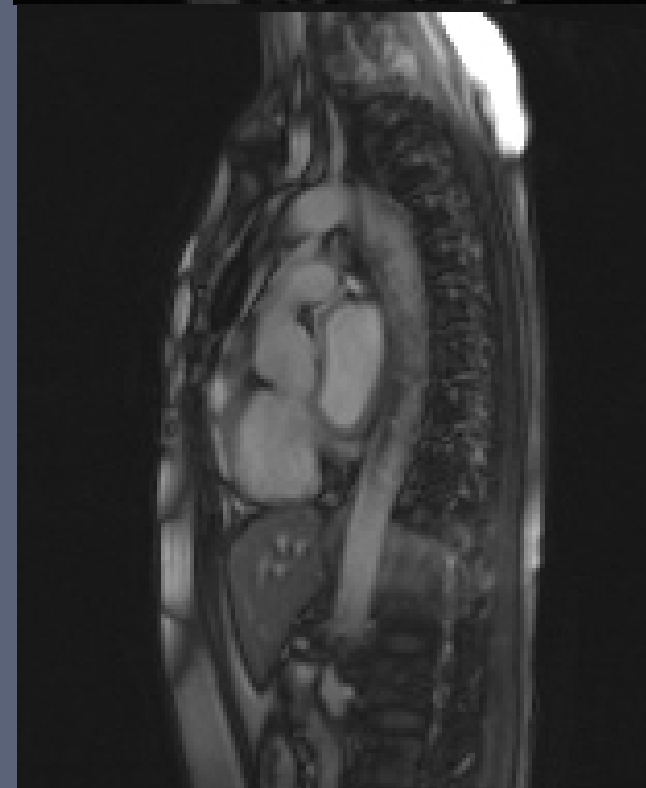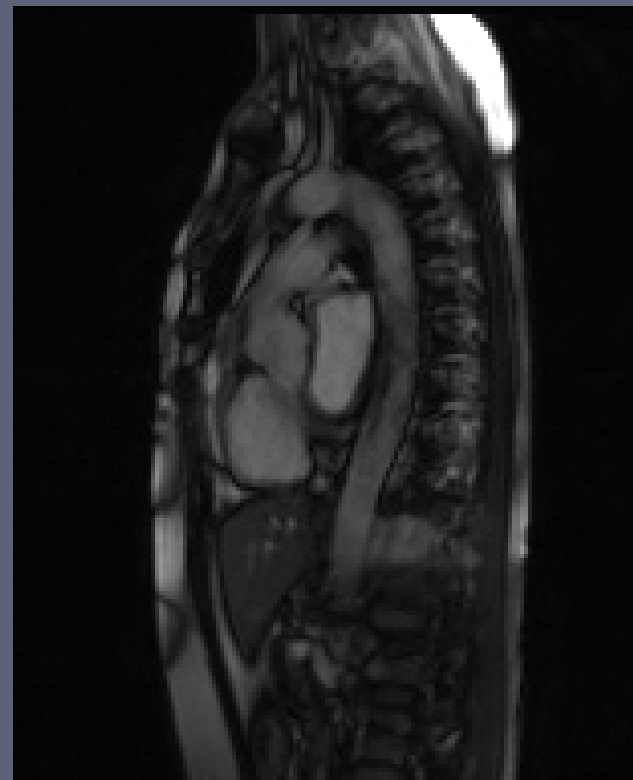
DE-sag



T1-sag-GD(+)-10min



Pre-CINE



Post-CINE